



**PATIENT**

Blackie Rosado

**SPECIES**

Canine

**BREED**

Chihuahua

**SEX**

Male Intact

**AGE**

11 years

**WEIGHT**

8lbs

**INTERPRETED BY**

Maggie Machen Lamy,  
DVM, DACVIM  
(Cardiology)

**IMAGING PERFORMED BY**

G. Ferrer, DVM

**HOSPITAL NAME**

Pulse: Pet Ultrasound  
Services

**REFERRING VET**

Dr. Carrasquillo

**INVOICE**

47668

**DATE**

4/26/26

**PRESENTING CLINICAL SIGNS**

History: Grade 3-4/6 heart murmur. Increased HR. Dry cough and exercise intolerance. Vetmedin started and symptoms have improved.

**RADIOGRAPHIC FINDINGS** \*NOTE: Images submitted for supplemental cardiac information only.

Mild cardiomegaly. No obvious evidence of CHF.

**ECHOCARDIOGRAM FINDINGS**

2D, m-mode, color flow and doppler imaging is available. Mild diffuse thickening of mitral valve leaflets with mild prolapse into the left atrial lumen. Mild eccentric mitral regurgitation with mild left atrial dilation. Normal MR velocity. Normal LV diameter with adequate myocardial function. The tricuspid valve appears normal with trace tricuspid regurgitation. Normal velocity. Normal right atrial and ventricular diameter and morphology indicating no overt evidence of pulmonary arterial hypertension. The pulmonic and aortic valves are normal in morphology and mobility. Normal pulmonic and aortic outflow velocities with laminar flow. No obvious aortic or pulmonic insufficiency. No pericardial or pleural effusion noted. No obvious cardiac masses.

**CARDIAC CHART**

CANINE CARDIAC PARAMETERS	MR VMAX (m/s)	TR VMAX (m/s)	LA/AO (Boon method)	LA/AO (Heart Base; Swe)	FS (%)	EF (%)	EPSS (cm)
<b>NORMAL PARAMETER</b>	4.5-5.5	<2.7	1.3	<1.6	28-40	40-100	<0.6
<b>PATIENT</b>	6.1	2.0	NM	1.7	58	89	0.2
CANINE CARDIAC PARAMETERS	HR (BPM)	AV VMAX (m/s)	PV MAX (m/s)	BODY WEIGHT (kg)	LA 2D short axis Base view (cm)	LVIDd Avg; 2D and m-mode short axis (cm)	LVIDs Avg; 2D and m-mode short axis (cm)
<b>NORMAL PARAMETER</b>	50-100	0.7-1.7	0.7-1.6	BELOW	BELOW	BELOW	BELOW
<b>PATIENT</b>	200	0.8	0.8	3.6	1.7	2.5	1.1
*Normal chamber parameters expressed as a mean value (SD)				3	1.27 (5.3)	2.46 (2.46)	1.36 (5.5)
<b>BODY WEIGHT DEPENDENT PARAMETERS</b>				5	1.40 (4.5)	2.74 (5.2)	1.60 (4.7)
*Note: All measurements based upon multi-modal images and methods. An average value is reported.				10	1.50 (3.8)	3.27 (3.5)	2.06 (3.1)
				15	1.83 (2.0)	3.71 (2.4)	2.43 (2.1)
				20	2.02 (1.9)	4.14 (2.2)	2.80 (2.0)
				25	2.18 (2.4)	4.48 (2.9)	3.10 (2.5)
				30	2.33 (3.3)	4.83 (3.9)	3.39 (3.4)
				35	2.48 (4.3)	5.17 (5.0)	3.69 (4.5)
				40	2.62 (5.2)	5.48 (6.1)	3.96 (5.4)
				50	2.88 (7.1)	6.07 (8.3)	4.46 (7.4)

**INTERPRETATION OF THE FINDINGS & FURTHER RECOMMENDATIONS**

Chronic degenerative valve disease causing moderate mitral and trace tricuspid regurgitation. Moderate left atrial enlargement indicates there is relatively low risk for imminent complication; however, risk for progression to spontaneous congestive heart failure in the future is elevated. No additional issues such as pulmonary hypertension are identified.



## PATIENT

Blackie Rosado

## SPECIES

Canine

## BREED

Chihuahua

## SEX

Male Intact

## AGE

11 years

## WEIGHT

8lbs

## INTERPRETED BY

Maggie Machen Lamy,  
DVM, DACVIM  
(Cardiology)

## IMAGING PERFORMED BY

G. Ferrer, DVM

## HOSPITAL NAME

Pulse: Pet Ultrasound  
Services

## REFERRING VET

Dr. Carrasquillo

## INVOICE

47668

## DATE

4/26/26

A change in HR is noted in the history. No comment can be made without an ECG.

Given these findings, continued Pimobendan is indicated in this patient as below. Assessment of progression in the future will help predict long term outcome; however, prognosis is guarded at this stage (B2). Fifty percent of stage B2 patients typically develop CHF within 2-2.5 years of diagnosis. The median time to development of CHF in B2 cases treated with pimobendan is 3.5 years.

While mainstem bronchi compression may certainly be contributing to an increase in coughing, other primary airway contributions should also be considered (tracheal collapse, COPD/chronic bronchitis, etc.). Consider hydrocodone for any mechanical component due to cardiomegaly. If the cough is poorly controlled and/or progresses long term, pulmonary hypertension (PAH) can develop secondarily. Signs of clinically relevant PAH include exertional dyspnea or exertional syncope. It is important to note that PAH does not cause the cough; rather, the cough leads to PAH.

Omega fatty acid supplementation and mild salt restriction may also be of some long-term benefit. Monitor for development of a progressive cough, labored breathing, exercise intolerance or collapse episodes.

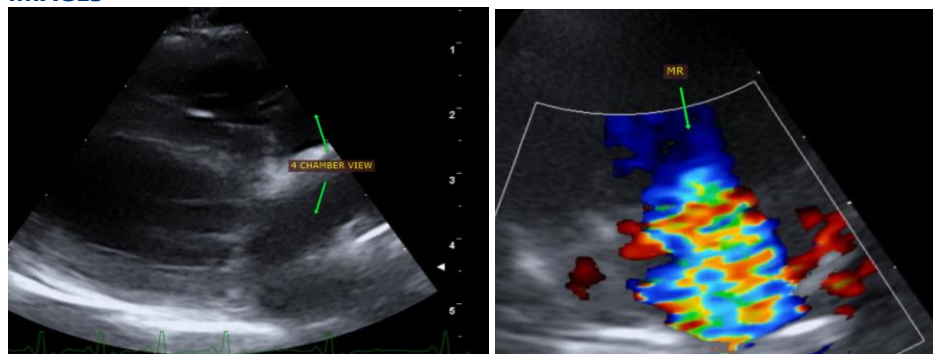
Anesthetic risk is considered mildly elevated. Pre-oxygenate for 5-10 minutes prior to induction. Cardiac protective drug choices (opioid/benzodiazepine premedication, Propofol or alfaxalone induction, iso or sevo gas) are recommended. Monitor for arrhythmias, hypotension, and/or hypoxia both intra and post-operatively and intervene as necessary. Judicious IV fluid rates are recommended to avoid fluid overload. Avoid heart rate stimulating drugs such as atropine unless clinically indicated.

## PLAN

ECG recommended Continue Pimobendan 0.3mg/kg PO q12h. Baseline BP recommended. Consider Hydrocodone and/or further cough evaluation as indicated.

Recommend monitor for progression with a recheck echocardiogram in 6 months, sooner if any development of additional clinical signs in the interim.

## IMAGES





## PATIENT

Blackie Rosado

## SPECIES

Canine

## BREED

Chihuahua

## SEX

Male Intact

## AGE

11 years

## WEIGHT

8lbs

## INTERPRETED BY

Maggie Machen Lamy,  
DVM, DACVIM  
(Cardiology)

## IMAGING PERFORMED BY

G. Ferrer, DVM

## HOSPITAL NAME

Pulse: Pet Ultrasound  
Services

## REFERRING VET

Dr. Carrasquillo

## INVOICE

47668

## DATE

4/26/26

**The information and recommendations provided are based on the images presented by the referring veterinarian. No evaluation can be communicated regarding pathology that was not visible in the image/video clips provided.**

Thank you for this referral. This report was generated using transcription software, and minor dictation errors may be present. If the clinical or image interpretation does not parallel your findings or if I can be of any further assistance, please contact me.

**Maggie Machen Lamy, DVM**  
**Diplomate of the American College of Veterinary Internal Medicine (Cardiology)**  
info@sonopath.com